

Muscle Volume Discrepancies in Hemiparetic Cerebral Palsy: A Comparative MRI Study Across Age Groups

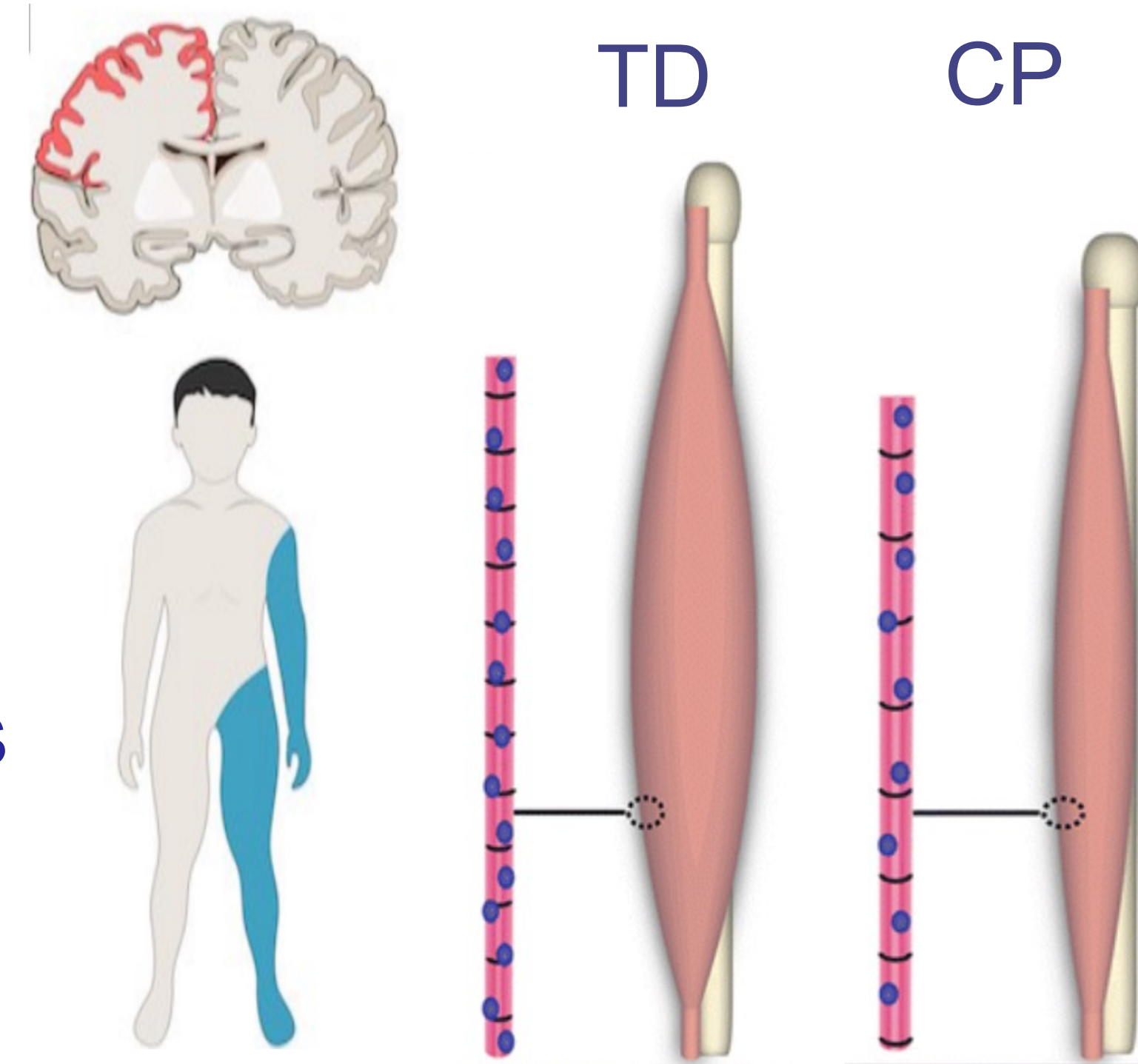
Nicholas Buto^{1*}, Maya Harkavy^{1*}, Jocelyn Kahn^{1*}, Jeffrey Yu^{1*}, Alexandra Hruby^{1,2}, Carson Ingo^{1,3}, and Divya Joshi^{1,2}

*Co-first authors, ¹Dept. of Physical Therapy and Human Movement Sciences, ²Dept. of Biomedical Engineering, ³Dept. of Neurology, Northwestern University Feinberg School of Medicine, Chicago, IL

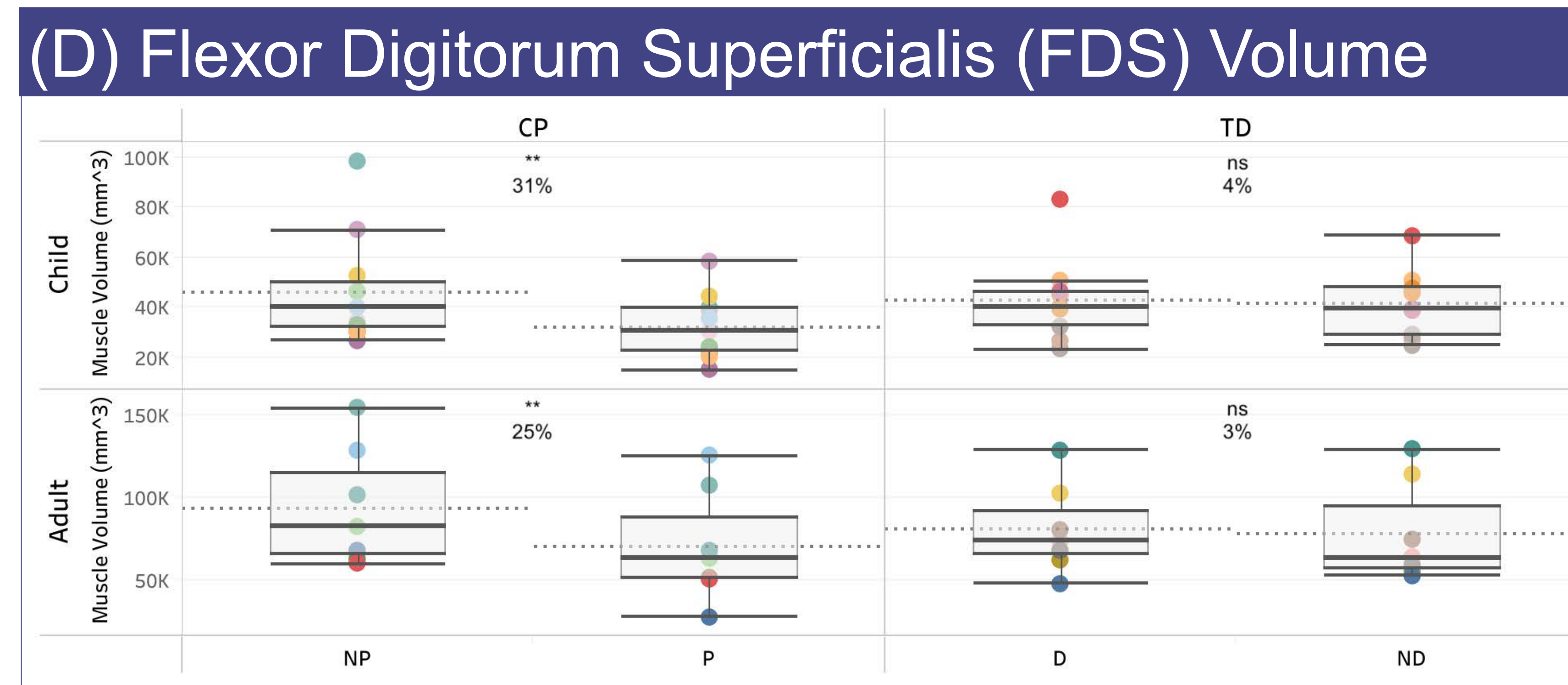
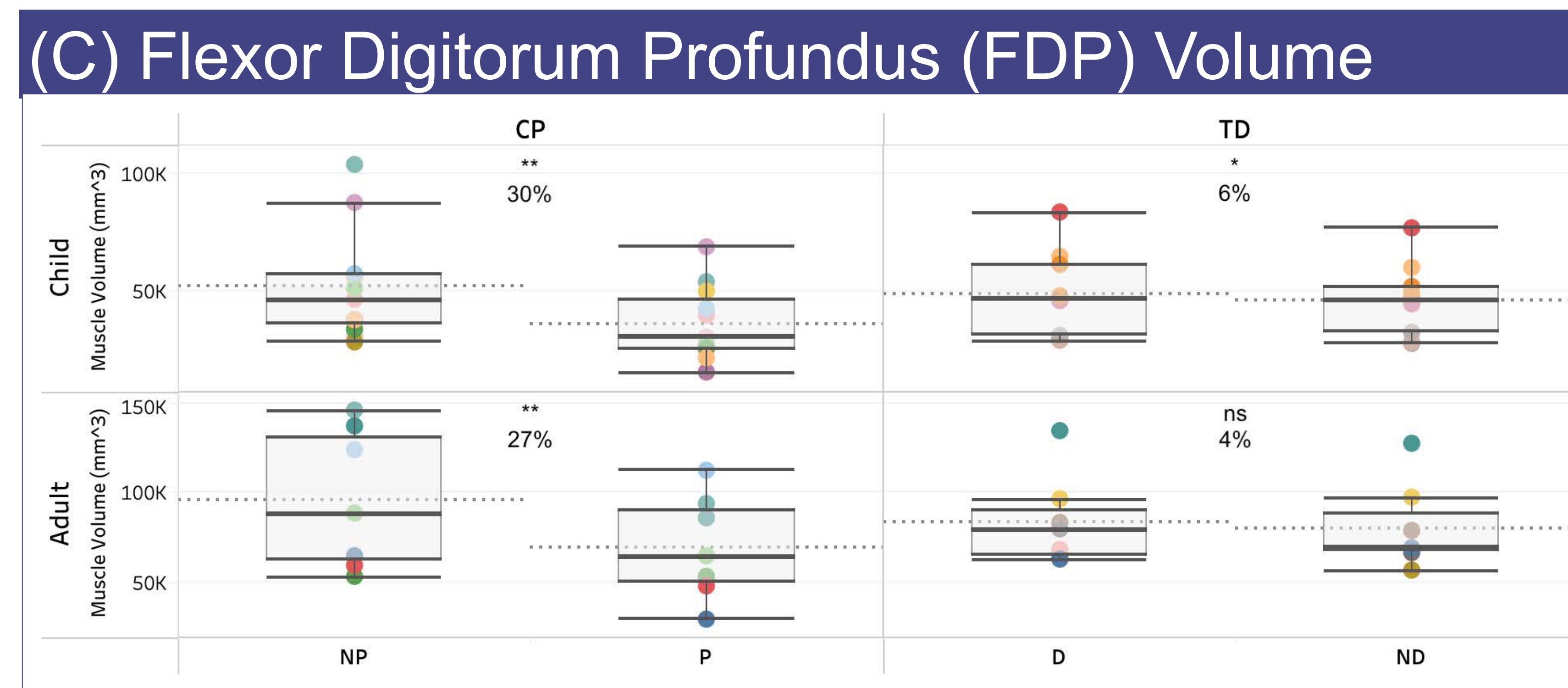
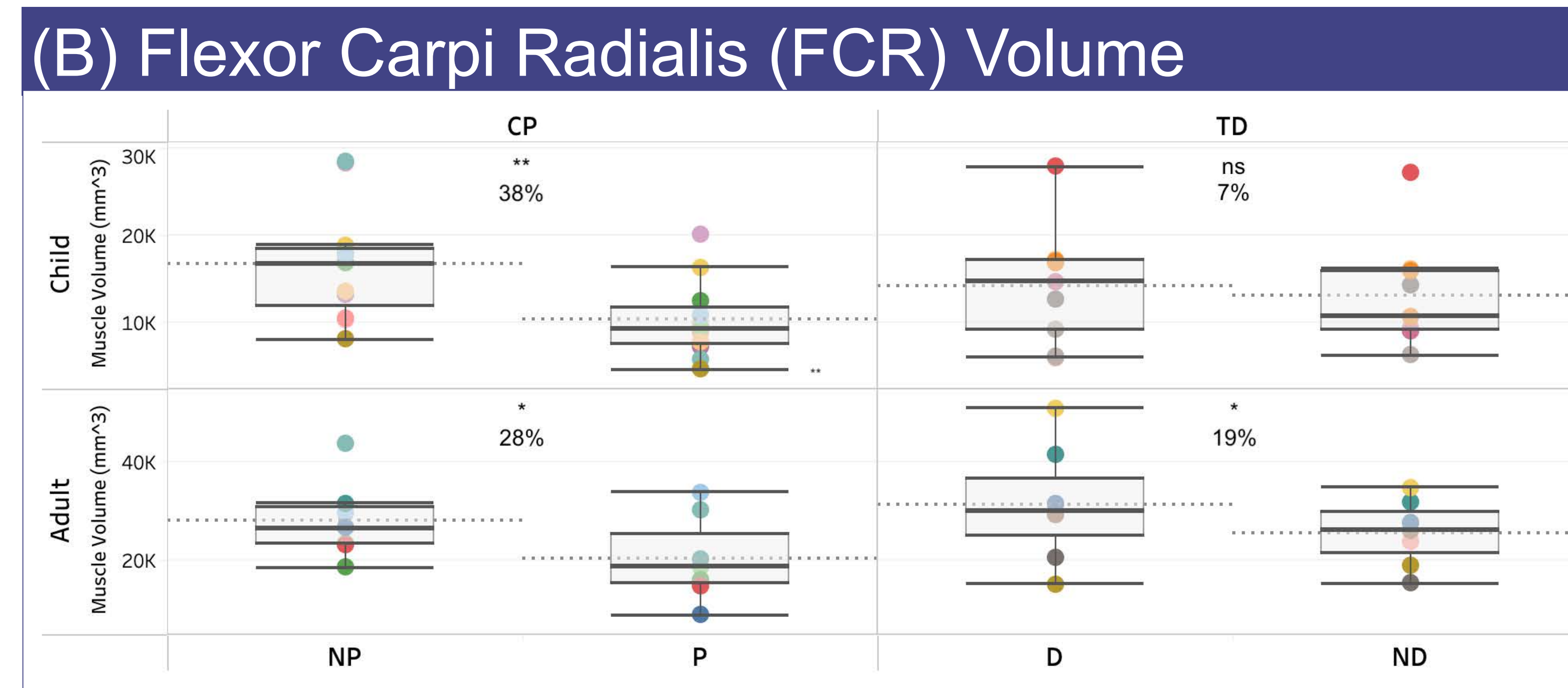
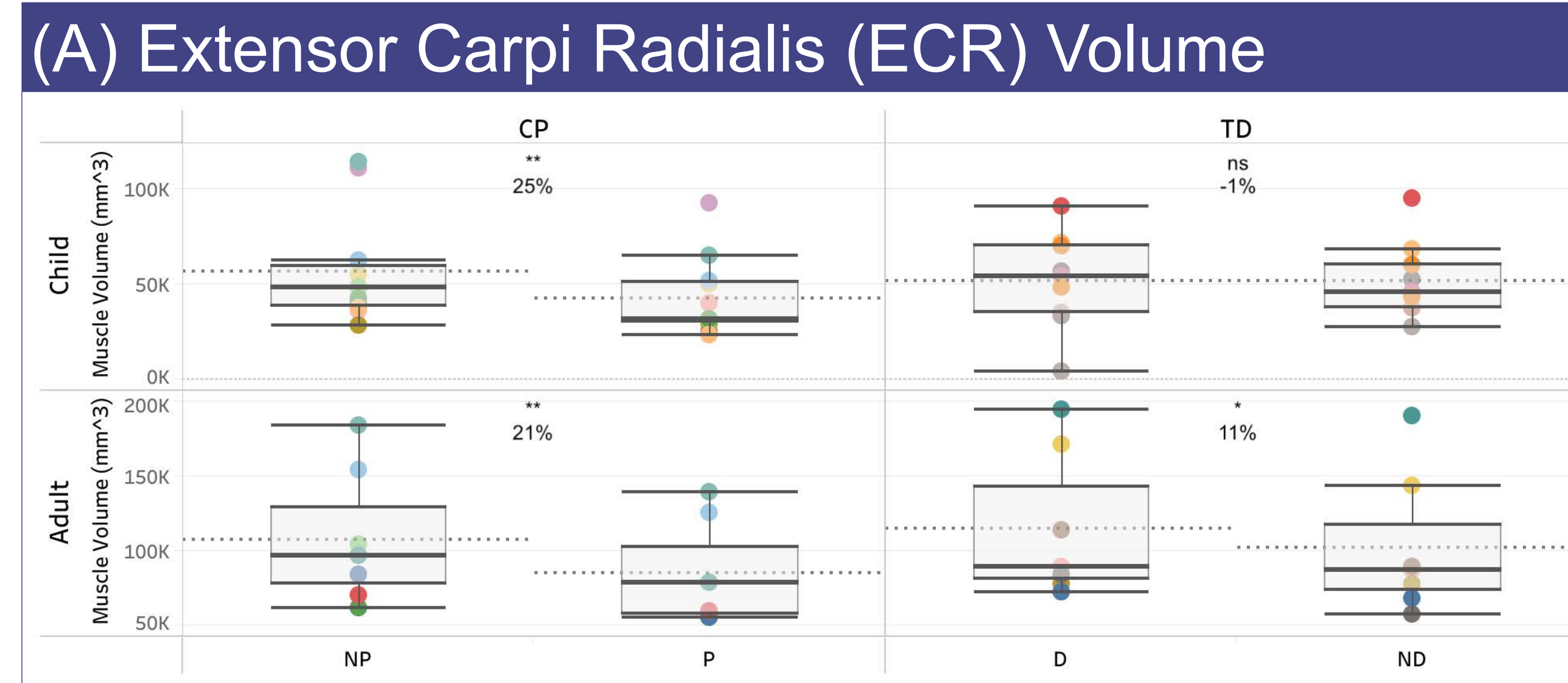
Background & Objective

- Cerebral palsy (CP) is the most common motor disorder in childhood, affecting 2 in every 1000 live births
- CP results in progressive secondary musculoskeletal changes that have a profound impact on lifelong development and function

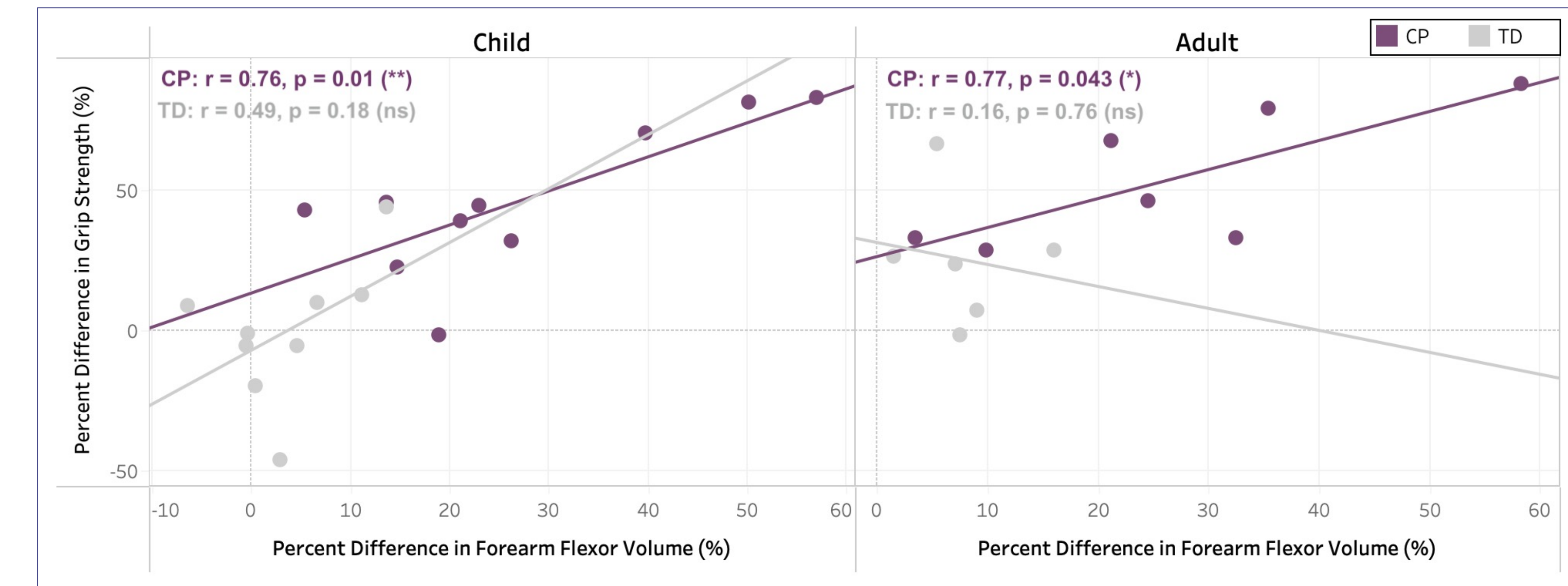
We aimed to determine if forearm flexor and extensor muscle volume interlimb differences vary between childhood and adulthood and examine the correlation between flexor muscle volumes and grip strength in individuals with CP and TD individuals.



Paretic Forearm Muscles Are Smaller in CP



Forearm Flexors Correlated to Grip Strength



Left: Volumes of the (A) ECR, (B) FCR, (C) FDP, and (D) FDS muscles by patient group and age group. Interlimb percent difference in muscle volumes are shown (positive indicates P/ND < NP/D). Top: Correlations between interlimb percent differences in grip strength and total forearm flexor muscle volume by patient group and age group. Positive interlimb percent difference indicates P/ND < NP/D. Linear regression lines and Pearson correlation coefficients are shown. For both: Significance levels shown are as follows: ns $p > 0.05$, * $p < 0.05$, ** $p < 0.01$, *** $p < 0.001$.

Conclusions

- Individuals with CP have reduced paretic muscle volume (21-38%)
- Children with CP showed more interlimb differences in muscle volume than adults with CP
- TD adults had larger wrist flexors/extensors in the dominant limb
- Children with CP often have difficulties with ADLs due to decreased motor function and strength in their affected limb(s) due to decreased muscle volume

Clinical Relevance:

- Need to promote the use of the paretic side starting early in childhood with interventions
- One clinically feasible method to quantify increases in muscle volume is to measure maximum grip strength

Acknowledgements & References

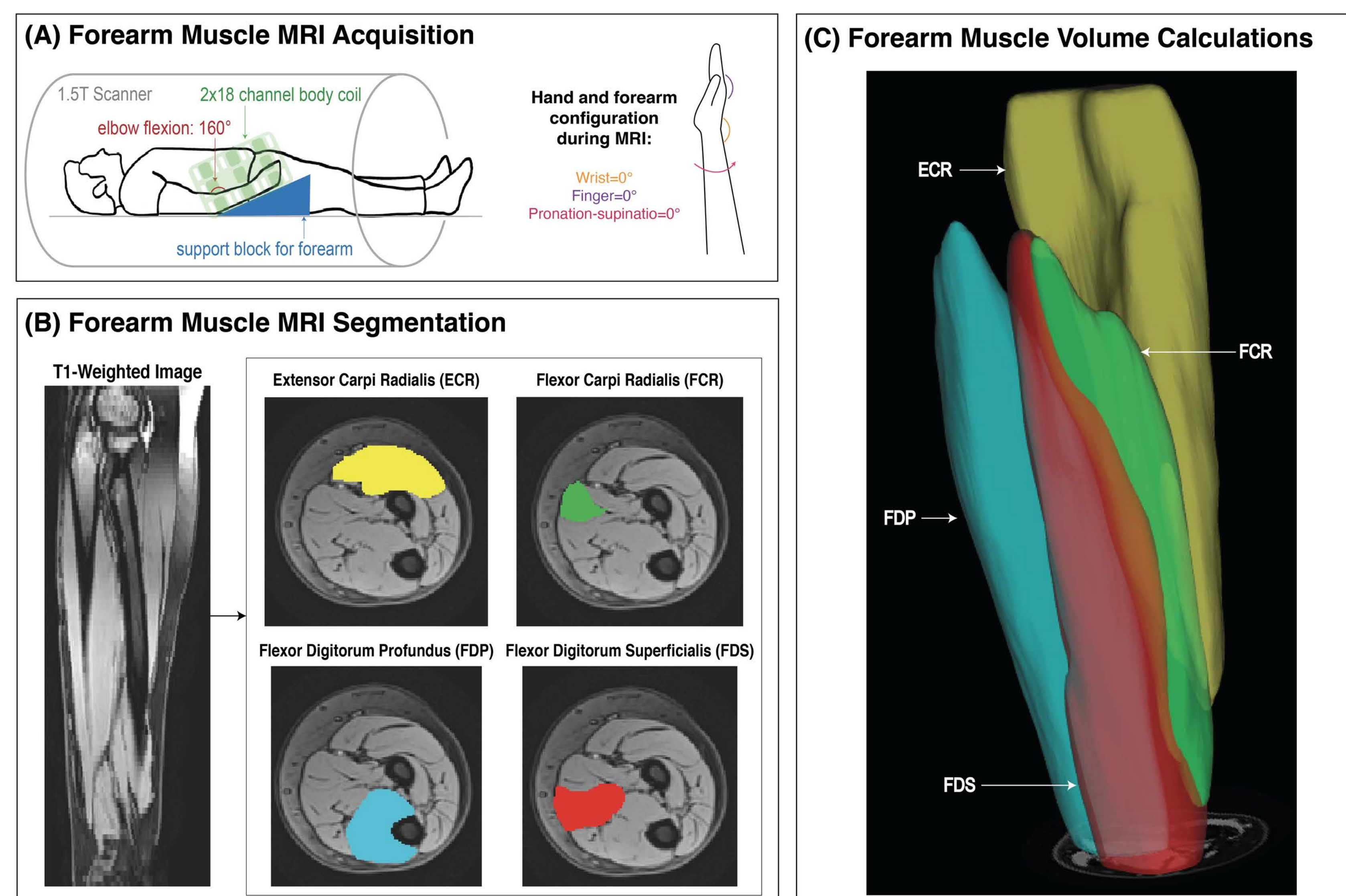
We thank Donny Nieto, Rachael Young, and Marie Wasielewski for their assistance with MR imaging. This work was funded by grants R01NS058667 and predoctoral fellowships F31HD110236 to DJ.

References:

- Barrett RS, Lichtwark GA. *Dev Med Child Neurol.* (2010)
- Handsfield GG, Williams S, Khuu S, Lichtwark G, Stott NS. *BMC Musculoskelet Disord.* (2022)
- Sahrman AS, Stott NS, Besier TF, Fernandez JW, Handsfield GG. *PLoS One.* (2019)
- von Walden F, Jalaaliddini K, Evertsson B, Friberg J, Valero-Cuevas FJ, Pontén E. *Front Comput Neurosci.* (2017)
- Park H, Choi JY, Yi SH, et al. *BMC Pediatr.* (2021)
- Dekkers KJFM, Rameckers EAA, Smeets RJEM, et al. *Phys Ther.* (2020)

Methods

MR Imaging & Muscle Segmentation



Study Sample Size

TOTAL: n = 34	CP	TD
Child	11	9
Adult	7	7